



VASC-ALERT ACCESS SURVEILLANCE CASE STUDY

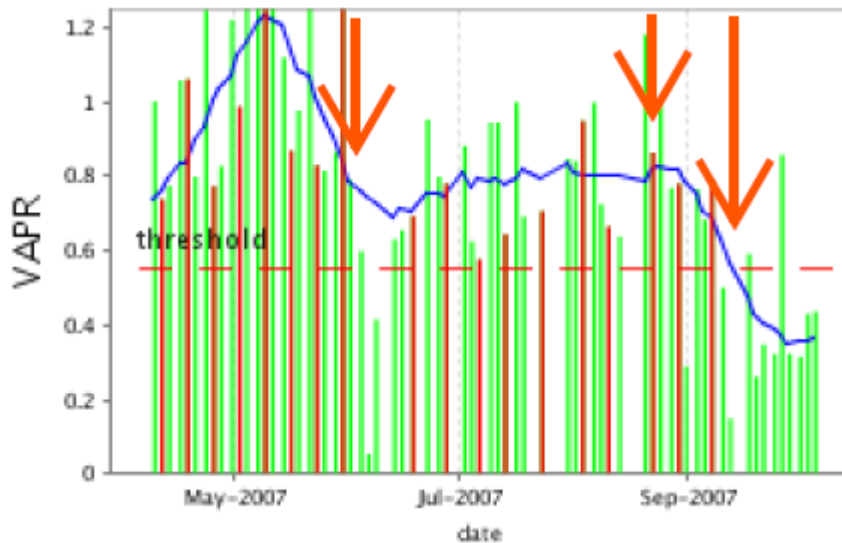
PATIENT PROFILE

77 year old female
Primary cause of ESRD: Hypertension
Dialysis start date: 6/26/02
Dialysis access: Brachioaxillary arteriovenous graft
Dialysis access placed: 6/22/02
Treatment time: 3 hours/180 minutes 3 times per week
Ordered BFR: 400 ml/min
Kt/V result at time of intervention: 1.88

There were no other clinical signs or symptoms that were indicative of access dysfunction or stenosis (e.g. no increase in venous pressure, no excessive bleeding, no decrease in blood flow, no difficulty in cannulation, no decrease in Kt/V), but the patient had consistent alerts.

VASC-ALERT DATA

Venous Access Pressure Ratio



This patient had multiple high readings and alerts issued by Vasc-Alert. In the above VAPR graph the vertical green and red lines indicate the average VAPR for the dialysis session. The vertical red lines occur on dates where an alert was issued. The horizontal red dashed line is a pre-set threshold value. The blue line is a moving average which is used to visualize the trend of the graph more easily. The red arrows indicate when an intervention took place. The dates on the graph are in month/year format. Gaps in data are typically due to a lack of source data (missed treatment or hospitalization) or incomplete source data. For example, calculations may not have been made due to missing access type, needle gauge or blood pressure data.

HISTORY AND EXAM

Left upper arm fistula created unknown surgeon. Revised with patch vein graft in July 2006. Had a complex clot in March with multiple lesions addressed. 1 month follow-up fistulogram in April showed recurrence of a cephalic arch lesion and mid humerus fistula stenosis. Both were

angioplastied. She had significant residual stenosis of the cephalic arch lesion. A 3 month follow-up study was scheduled. Indication for referral is history of a dysfunctional fistula. The patient had consistent, elevated VAPR results and was sent for an angiogram in 4/07 and on 7/3/07. The access was determined to have a significant stenosis. The red arrows on the graph indicate the intervention dates, and a drop in VAPR values below the threshold is seen after the procedures.

PROCEDURE

The patient's left arm was prepped and draped in the usual sterile fashion. Lidocaine was used for local infiltration. An 18-gauge needle was used to cannulate the fistula facing downstream. The 0.035-inch Angio Bentson guidewire was advanced up the arm, and a 7 French sheath was inserted over the wire. Venogram revealed 80% stenosis involving the cephalic arch. The rest of the fistula and draining veins all the way to the SVC appeared widely patent. There is a small to moderate aneurysm in the mid-humerus portion of the fistula.

A retrograde brachial arteriogram revealed stenosis of the inflow with a corkscrew appearance. The stenosis is in the order of 60-70%. A good portion of the brachial artery before and after the arterial anastomosis was visualized.

Medications were given to achieve adequate conscious sedation. A 9X4 conquest balloon was deployed to the cephalic arch and used to angioplasty the lesion. A follow-up angiogram showed recoil lesion with 60% stenosis. The balloon was again used for angioplasty. Pressures were held for 2 full minutes. Another venogram showed an elastic 40-50% lesion, unamenable to further angioplasty.

A 2nd cannulation of the fistula was necessary to access the inflow for angioplasty. A roadrunner variant by Cooks was advanced with moderate difficulty across the arterial anastomosis. A 6X4 workhorse balloon was then insufflated to pressures of 10 atm. There was significant stricturing of the balloon, consistent with 70% stenosis. A follow-up arteriogram showed improvement of the lesion but residual 20-30%.

Hemostasis was obtained with a z-stitch at the cannulation sites. The patient tolerated the procedure. The interventionalist suspects the cephalic arch lesions will be an ongoing concern.

FINDINGS

1. Dysfunctional arteriovenous fistula, left upper arm brachial cephalic
2. Elastic, recoiling cephalic arch stenosis 80%
3. Arterial anastomosis stenosis, 70%

SUMMARY

The patient was sent for access angiography and found to have a hemodynamically significant stenosis that was treated by angioplasty. Shortly after intervention the patient's VAPR results returned to normal and fell below the threshold.